

Cone beam volume imaging (CBVI) 3D applications for dentistry

Robert A Danforth and Dale Miles discuss the impact of cone beam volume imaging on dentistry

The hallmark of dentistry in the new millennium is 'computer assisted dentistry' and nothing characterises this more than the impact 3D cone beam computed volume imaging/tomography (CBVI/CBVT) has had upon diagnosis, treatment planning and direct delivery of patient dental care.

In less than a decade, CBVI has revolutionised oral and maxillofacial radiology. Although development was initially directed towards multi-planar viewing for dental implant and orthodontic treatment planning, secondary applications in other areas continue to expand because dentists find they are no longer confined to 2D, greyscale imaging and it provides information previously unobtainable (see Table 1).

The intent of this article is to provide a brief overview of

dental CBVI technology and examples of applications. While this technology has been almost universally described as CB computed tomography (CBCT), use of this term associated with the introduction of this

technology created some concerns that this was in reality a medical device and, as such, should not be directly available to dentists for operation. This was particularly a concern in the USA and various terms such

as CBVI or CBVT were used to differentiate this connection with medical CT. In this article, CBVI is used to continue the differentiation.

Descriptions of CBCT devices for dentistry first appeared in the late 1990s with reports from Italy and Japan describing the development of prototype machines (Mozzo P et al, 1998; Arai Y et al, 1999). The first devices to become commercially available were the Newton QR 9000 (QR Italia, Verona, Italy) and the 3DX Accuitomo (J Morita, Kyoto, Japan), which were initially introduced into the European and Asian markets. These were soon followed by the MercuRay (Hitachi, Japan, Twinsberg, OH, USA) and the i-CAT (Imaging Sciences, Hatfield, New Jersey, USA). All of the devices are capable of providing complete or partial skull fields of view (FOV) except for the 3DX Accuitomo, which is a regional quadrant device with a field size of 40 x 30mm.

Currently, there are approximately a dozen different machines either available, receiving government approval or in development (see Table 2). Some of the recent machines have specifically targeted a limited FOV favouring regional, quadrant and dental arch imaging similar to the initial Accuitomo device. Such an approach appears directed toward providing cost-effective 3D imaging for the general practice market (Farman AG, Levato CM, Scarfe WC, 2007; Miles DA,

Table 1: Current dental applications of CBVI

1. Primary applications

Pre-surgical implant site assessment

Inferior alveolar nerve location

Alveolar ridge configuration

Spatial relationships of anatomical structures

Surgical guide construction

Orthodontic assessment

Cephalometric and space 1:1 analysis

Temporomandibular joint evaluation

Multi-planar views, dentition relationship

Extraction cases

Impactions, third molars/nerve location, canines

Supernumerary teeth

2. Secondary applications

Paranasal sinus evaluation

Airway studies for sleep apnoea

Visualisation of jaw pathology

Trauma evaluation

Endodontic evaluation

3D virtual models

TADs (Temporary anchorage devices)

Other CAD/CAM devices

Robert A Danforth DDS is a Diplomate of the American Board of Oral and Maxillofacial Pathology and an Associate Professor of Clinical Sciences at the University of Nevada Las Vegas School of Dental Medicine.

Dale Miles DDS, MS, FRCD(C) is a Diplomate of the American Board of Oral and Maxillofacial Radiology and an Adjunct Professor at the Arizona School of Dentistry & Oral Health and the University of Texas at San Antonio.

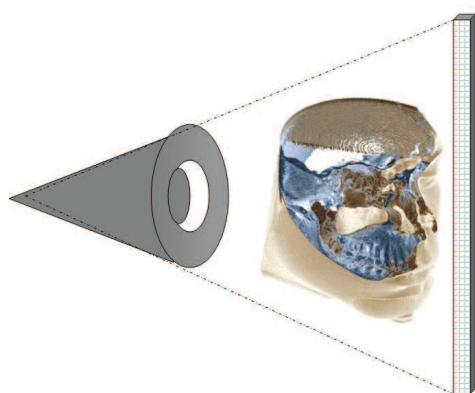


Figure 1a: Cone-shaped beam rotates about head once

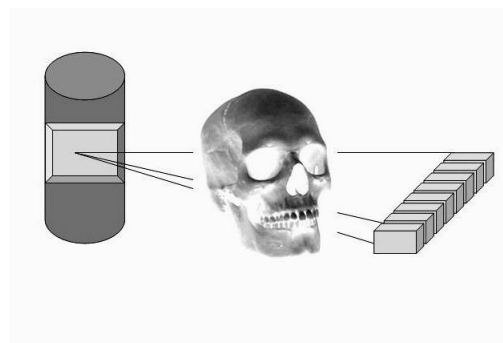


Figure 1b: Fan-shaped beam rotates about patient's head hundreds of times, acquiring thin horizontal or axial sections

Danforth RA, in press; Hayakawa, 2007).

How does it work? Why is it a better option for dentistry than medical computed tomography (CT)?

Most of the CBVI 'stand-alone' devices look like a panoramic machine and the patient either sits or stands during the examination. By contrast, the NewTom 9000, NewTom 3G and the newer SkyView machines look like mini medical CT scanners and the patient lies in the supine position. However, the newest version of the Newtom VG, marketed by Dent-X/AFP, will be a stand-up version. While some companies have previously produced panoramic machines, currently only the Planmeca ProMax CBVT is actually 'upgradeable' from an existing panoramic platform.

Depending upon the imaging device, image

capture is generally a single 190°-360° scan sweep around the patient's head. The X-ray beam is a 'cone beam' shape aimed at a solid-state flat panel detector that covers the desired image volume in a single scan. The 'fan-shaped beam' employed in traditional medical CT requires multiple repeated slice scans to accomplish a similar image volume (Figures 1a and 1b).

This single scan CBVI approach is very successful at decreasing the patient's absorbed X-ray dose from six to 15 times during the 3D imaging examination when compared to medical CT (Farman AG, Levato CM, Scarfe WC, 2007).

The cone beam scan results in several hundred dimensionally accurate isotropic images of the patient from different positions around the scan rotation. Data is immediately transferred to the computer,

which reconstructs it, in approximately three to six minutes depending upon the machine, into the anatomical volume for viewing at a precise 1:1 ratio with accurate dimensional measurements within 1/10mm made across different tissue planes.

Once reconstructed, multi-planar viewing of the anatomical volume is accomplished with the imaging software. Volume data is saved in a DICOM (Digital imaging and communication in medicine) file format to facilitate sharing images between clinicians and other imaging related services.

Most manufacturers also provide a simpler 'user' PC viewing program that contains basic 3D imaging tools. This allows referral sources to participate in limited 3D imaging without having to purchase expensive software. For clinicians who wish to plan their implant cases more actively, third party software is available at a wide range of cost.

Applications and a new perspective for interpretation, diagnosis and treatment planning

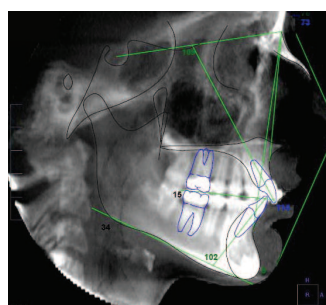
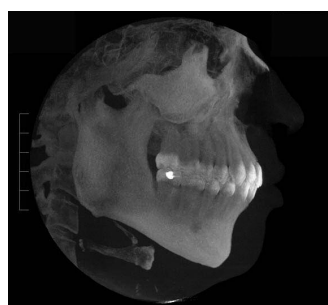The results of computer-generated 3D visualisation of multi-planar images are new applications that improve interpretation, diagnosis and treatment planning.

Imaging for orthodontic

Table 2: CBVI devices and manufacturer 2007

1. NewTom 3G, VG: Dent-X, Elmsford, New York, USA
2. Accuitomo 3DX: J Morita, Kyoto, Japan
3. i-Cat: Imaging Sciences (Danaher owned), Hatfield, Pennsylvania, USA
4. CB MercuRay, CB Throne: Hitachi Medical Systems, Twinsberg, OH, USA
5. Iluma: Imtec Corporation (Kodak distribution), Ardmore, Oklahoma, USA
6. Galileos: Sirona Dental Systems, Bensheim, Germany
7. ProMax 3D CBVT: Planmeca, Helsinki, Finland
8. SkyView: MyRay Dental Imaging, Imola, Italy
9. TeraRecon: Yoshida Dental Manufacturing, Tokyo, Japan
10. Alphard and PSR900N: Asahi Roentgen, Kyoto, Japan
11. Scanora 3D: Soredex (PaloDex), Tuusula, Finland
12. PicassoPro: eWoo (Gyeonggi-do, Korea)

Figures 2a and Figure 2b: Lateral cephalometric Images made using Multiple Image Planes (MIP). Figure 2a (left) shows MIP Images with soft tissue profile and Figure 2b (right) shows an image with orthodontic measurements using software developed for CBVI



CLINICAL

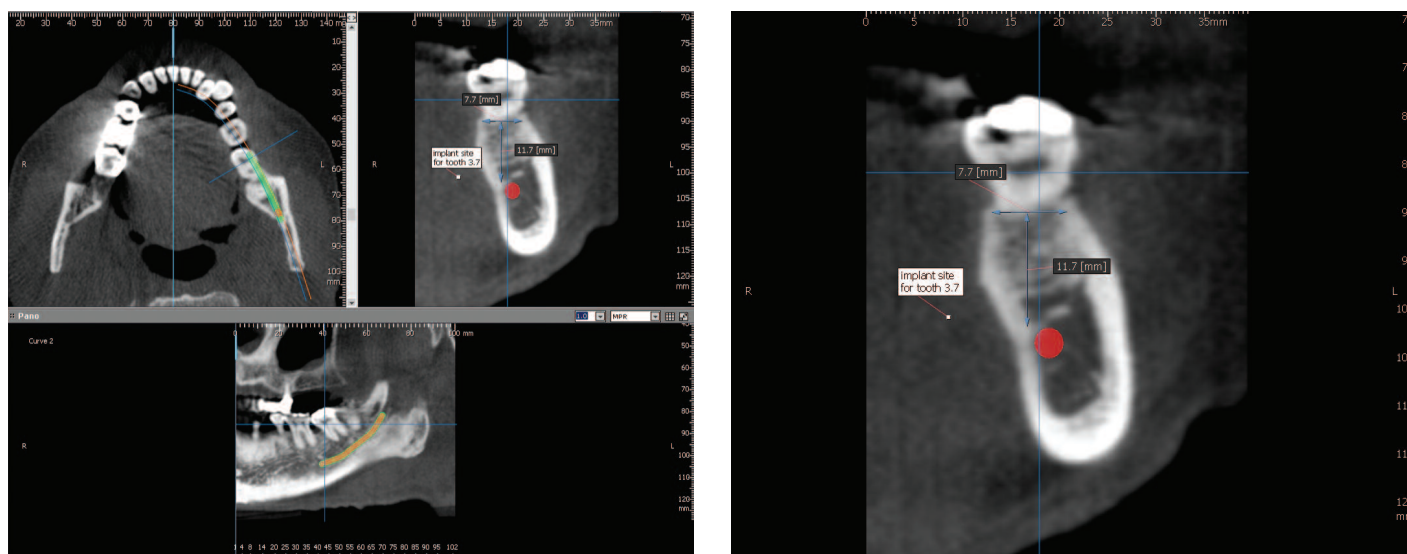


Figure 3a: Analytical image to render inferior alveolar canal structures visible in colours and precise Implant site measurements. The proposed Implant fixture may now be placed without fear of impinging on the inferior alveolar nerve

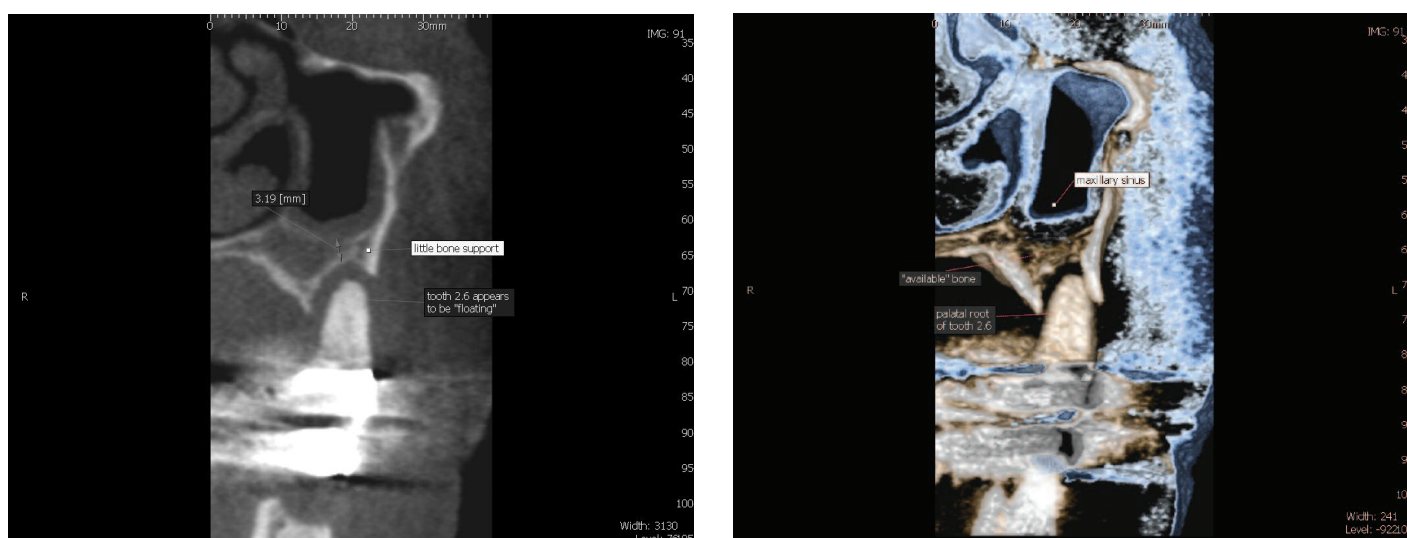


Figure 3b: Proposed Implant site of tooth to be extracted showing insufficient bone, periapical disease and associated inflammatory changes in maxillary sinus. Clearly, there is other treatment necessary before even attempting placement of an endosseous Implant in this site

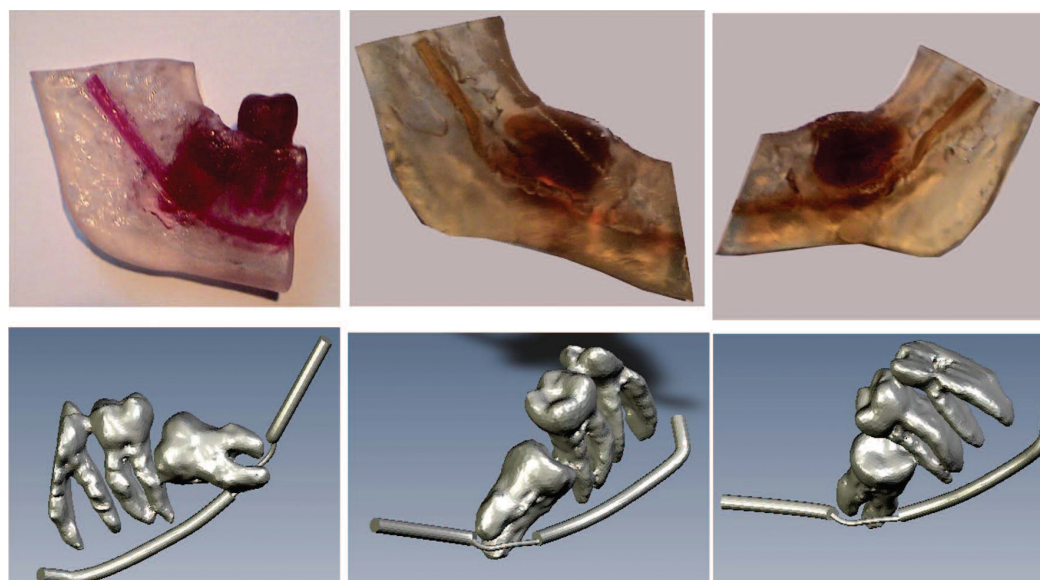


Figure 4:
Top row: reconstructed laser-generated resin models from CBVI volume images to assist surgical treatment planning for impacted third molars at risk of injury to the inferior alveolar nerve

Bottom row: visual models segmented from CBVI image data. Interactive tools allow for rotation, measurements and image 'slicing and dicing' to assist surgical planning

the orthodontic 1:1 ratio cephalometric measurements for treatment planning and several software programs have been developed for this purpose (Figure 2).

There has also been a tremendous impact upon dental implant treatment and treatment planning. Arch and ridge configuration, location of the nerve canals and sinus cavities can now be specifically identified prior to surgery, thus decreasing surgical uncertainty and potential patient morbidity (Figures 3a and 3b).

Besides mere visualisation of cross-sectional imaging of jaw site locations, innovative software programs have been developed to make custom precision surgical guides, virtual models and laser-generated resin models, all of which advance treatment planning and assist delivery capabilities (Figure 4).

The advantage of these innovative changes is that they are relatively cost-effective and readily available to the dentist. Direct fabrication of dental appliances from CBVI data using CAD/CAM (computer assisted design/computer assisted manufacturing) systems would seem a next progressive development.

Beyond dental – 3D image volume produces new interpretation responsibility

Although CBVI has created exciting new 3D methods for dental applications, it has also created increased responsibility for image interpretation. Unlike superimposed 2D imaging, a large volume of viewable collected patient data exists outside of the specific region of interest (ROI) in the multi-planar sections. Such image data must be viewed in the X, Y and Z planes to ensure that a comprehensive evaluation has been performed and documented (Miles DA, 2006). Failure to recognise these or to act upon them could result in various pathologic conditions going undetected that could

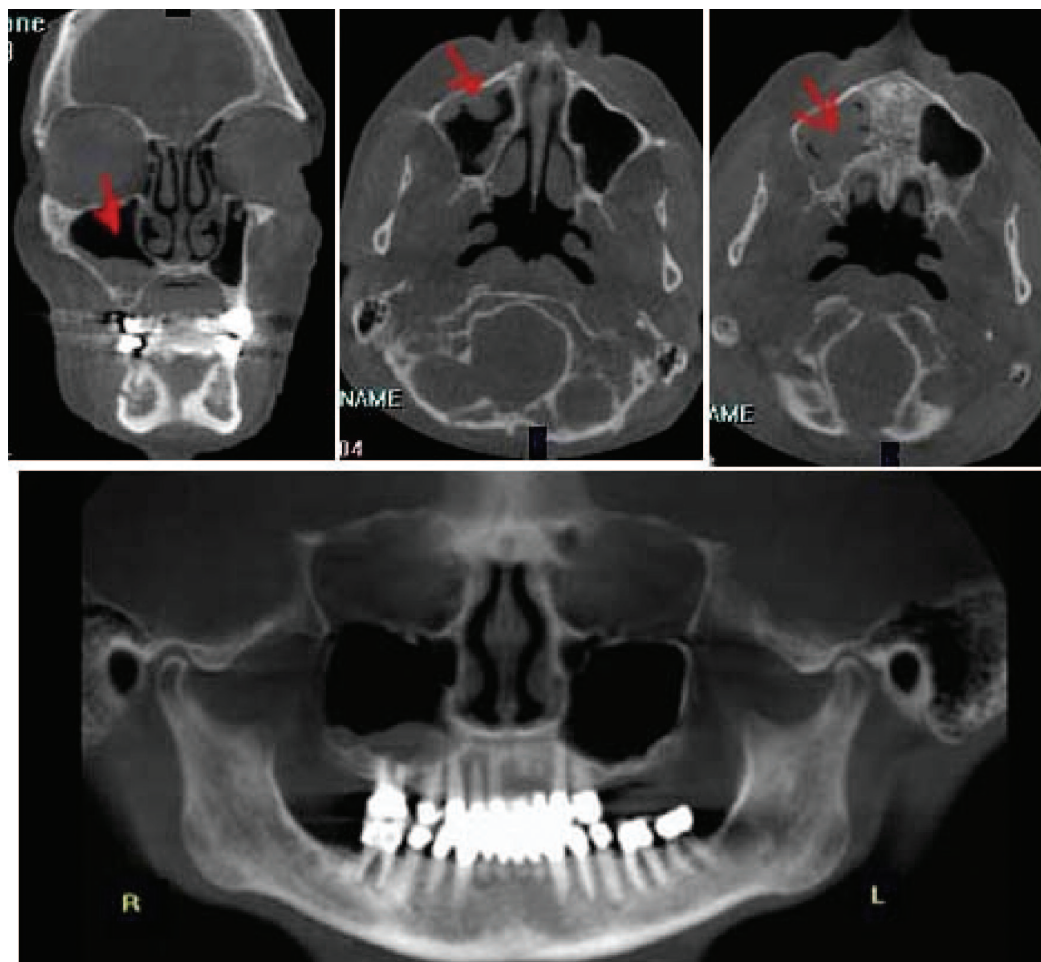
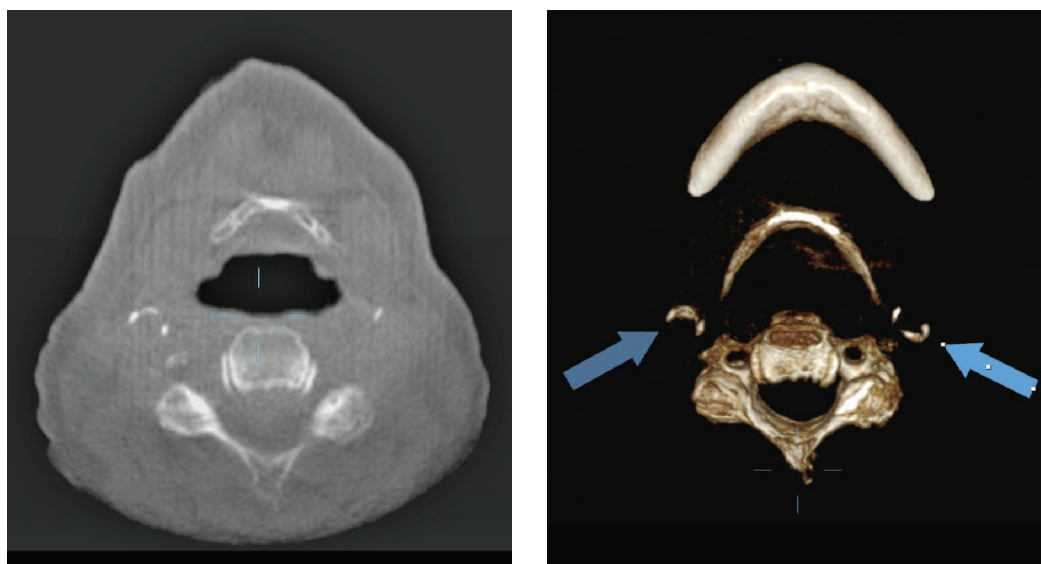


Figure 5a: The extent of right maxillary sinus disease is shown using multiple plane reviewing and a reconstructed panoramic image. Use of such techniques better defines the location of the disease and any impact it may have on the proposed treatment plan



Figures 5b and 5c: Bilateral circular calcifications in the region of the carotid sheath at the level of C3/C4 consistent with MAC (medial arterial calcinosis) seen in diabetic patients especially with end-stage renal disease (ESRD)

have a negative outcome on either the provided treatment or, worse, patient health and longevity.

Table 1, part 2 indicates that sinus and airway are applications for evaluating the presence of conditions

involving pathologic lesions, sleep apnoea or head and neck artery calcifications. In some cases, these may be

CLINICAL

secondary/incidental but life-threatening findings that are most likely located outside the jaws in non-ROI 3D multi-planes. As such, many dentists may not be as familiar or comfortable with looking for or interpreting these conditions.

Despite any unfamiliarity, many recent reports (Friedlander AH, Garrett NR, Norman DC, 2002; Miles DA, Craig RM, 1983; Almog DM et al, 2002; Magliocca KR, Helman JI, 2005; Kumar V et al, 2007) indicate dentistry has a role in such conditions as:

- Airway sleep apnoea problems
- Sinus conditions
- Bisphosphonate jaw osteonecrosis
- Awareness of carotid and other arterial calcifications as an indicator of potential stroke or advanced diabetic/renal problems.

These are examples of expanded regions of concern and responsibility where CBVI can assist detection of these conditions. In these circumstances, referral to a diagnostic imaging radiologist/specialist for an interpretative report of the 3D data volume is recommended (Figures 5a, 5b and 5c).

Conclusion

Any clinician reviewing the application list in Table 1 knows the limitations imposed by 2D imaging in a 3D world when interpretive diagnostic dilemmas arise in these areas. The length of the list indicates that, actually, no aspect of dentistry is free from such dilemmas. Until CBVI, when confronted with such situations, clinicians either chose medical related CT imaging or continued to


rely upon their traditional interpretation of 2D imaging despite inherent disadvantages.

CBVI imaging provides relief for clinicians from 3D mental reconstructions by using outstanding computer-assisted 3D imaging technology for multi-planar image visualisation, diagnosis and treatment planning.

The CBVI data obtained is similar to that from a high-end medical CT scan, but at a lower financial cost to the patient and at a much reduced radiation dose to the patient (Ludlow JB et al, 2006).

Since these devices are becoming widely available in both dental practices and dental imaging centres, reliance upon experience-based guess-estimations is being replaced by accurate imaging technology. As such, treatment outcomes are improved and both patients and dentistry benefit.

Despite these obvious advantages, comprehensive 3D image evaluation associated with CBVI is a new responsibility for dentistry

that must be accomplished in order to comply with the ethics of comprehensive patient care. 

References

- Almog DM et al (2002) Correlating carotid artery stenosis detected by panoramic radiography with clinical relevant carotid artery stenosis determined by duplex ultrasound. *Oral Surg Oral Med Oral Path Oral Radiol Endod* **94**: 768
- Arai Y, Tammsalo E et al (1999) Development of a compact computed tomographic apparatus for dental use. *Dentomaxillofac Radiol* **28**: 245-8
- Farman AG, Levato CM, Scarfe WC (2007) A primer on cone beam CT. *Inside Dentistry* **1**: 90-93
- Friedlander AH, Garrett NR, Norman DC (2002) The prevalence of calcified carotid artery atheromas on the panoramic radiographs of patients with type 2 diabetes mellitus. *JADA* **133**: 1516-23
- Hayakawa Y (2007) Newly added oral and maxillofacial radiology imaging technologies. *AADMRT winter newsletter*
- Kumar V, Pass B, et al (2007) Bisphosphonate-related osteonecrosis of the jaws. *JADA* (**138**): 602-609
- Ludlow JB, Davies-Ludlow LE, Brooks SL, Howerton WB (2006) Dosimetry of three CBCT devices for oral and maxillofacial radiology: CB Mercuray, NewTom 3G and i-CAT. *Dentomaxillofac Radiol* **35**: 219-226
- Magliocca KR and Helman JI (2005) Obstructive sleep apnoea: diagnosis, medical management and dental implication. *JADA* **136**: 1121-1129
- Miles DA and Craig RM (1983) The calcified facial artery: a report of its panoramic appearance and incidence. *Oral Surg* **55**(2): 214
- Miles DA (2006) Clinical experience with cone beam volumetric imaging: report of findings in 381 cases. *US Dentistry* **1**(1): 39-41
- Miles DA, Danforth RA (in press) *A clinician's guide to understanding cone beam imaging*, PennWell
- Mozzo P, Proccacci A et al (1998) A new volumetric CT machine for dental imaging based on the cone beam technique: preliminary results. *Eur Radiol* **8**: 1558-64

For more information on CBCT and volumetric images go to www.learndigital.net.

Table 3: Viewing software for clinicians

SimPlant: Materialise, Leuven, Belgium

VIP (Virtual Implant Placement): Implant Logic, Systems, Cedarhurst, NY, USA

V Implant, CB Works, Accurex, On Demand 3D: CyberMed International, Seoul, Korea

In Vivo: Anatomage, San Jose, CA, USA

NobelGuide: Nobel Biocare, Göteborg, Sweden



Look out for our special supplement on implants in the next issue of *Irish Dentist*. To include your company details, send 150 words plus an image to siobhan.lewney@fmc.co.uk today.