

The agony and ecstasy of buying cone beam technology

Part 1: The Ecstasy

Dale A. Miles¹

Abstract

Background: Since arriving in North America in 2001, cone beam computed tomography (CBCT) has been rapidly and enthusiastically embraced by the dental profession. With nearly two dozen CBCT systems currently available, dental providers are faced with a number of options when they consider purchasing this new technology. This aim of this article is to present introductory information on cone beam machines, the wide array of applications made possible by the incredible variety of image output choices, and decision points to aid the reader in their decision making process for purchasing CBCT systems. **Methods:** The author reviews a number of CBCT articles published in dental literature and draws upon his personal experience from analysis of over 3,700 CBCT cases. **Results:** CBCT applications, image outputs and decision points for purchase are discussed. 5 cases with various CBCT applications are discussed. **Conclusion:** Use of CBCT technology provides unique and valuable information that is unobtainable in any other format. This information can benefit practitioners in all aspects of dental treatment.

Key words: Cone beam computed tomography, digital radiography, radiographic image enhancement

Introduction

Cone Beam Computed Tomography (CBCT) has been rapidly and enthusiastically embraced by the dental profession in a much more dramatic way than “digital x-ray imaging”. Introduced in 1988, it has taken our profession over 20 years to reach a 40% adoption level with digital x-ray systems. In contrast, since arriving in North America in 2001¹, cone beam manufacturers have gone from one available system, the NewTom (initially QR Systems, Verona, Italy – acquired by AFP Imaging Corporation, Elmsford, NY), to over 13 currently available systems. This does not count companies making more than one version of their machine. A previous publication by Cattaneo and Melsen,² to which the reader is

referred for an excellent CBCT resource, gives a more complete description of machine parameters such as scan size, voxel size, kilovoltage, and milliamperage.

Because of the rapid introduction and adoption of CBCT technology, dentists and dental specialists have been offered so many choices that the decision making process is as complex and difficult as it was for digital x-ray adoption. The primary difference, however, is the huge cost of cone beam machines which can range in price from \$120,000 to \$350,000! Despite this enormous investment, dentists are discovering the advantages of cone beam imaging and taking the plunge.

In the first part of this article, “the Ecstasy”, I present introductory information on cone beam machines, the wide array of applications made possible by the incredible variety of image output choices, and some decision points to help you decide which cone beam device might best suit your practice.

¹ Dale A Miles, BA, DDS, MS, FRCD, Professor of Oral and Maxillofacial Radiology, Arizona School of Dentistry & Oral Health; Adjunct Professor, University of Texas Dental School, San Antonio, USA. Full-time practice, Oral & Maxillofacial Radiology, Fountain Hills, Arizona, USA.

The ecstasy of CBCT: applications, image output and decision points for purchase

Many recent articles on CBCT have reported quite a number of applications.³⁻⁸ While these current applications may change somewhat over time, table 1 presents what I feel will be the primary applications that may become the “standard of care” or commonplace for particular dental tasks.⁹

The cases below graphically illustrate the impact of CBCT

Table 1

| Clinician | Task(s) |
|---------------------------------------|--|
| General Dentist | Implant site assessment TMJ evaluation Paranasal sinus evaluation Airway analysis (sleep disorders) |
| Endodontist | Root form, pulp canal assessment Periapical lesion assessment Implant site assessment “Re-treatment” |
| Orthodontist | Space analysis Impactions Treatment “records” Craniofacial anomaly assessment TMJ evaluation Supernumerary tooth assessment |
| Oral and Maxillofacial Surgeon | Third molar assessment Orthognathic surgery Pre-surgical planning for lesions Paranasal sinus evaluation TMJ evaluation |
| Pediatric Dentist | Tooth development |
| Periodontist | Bone grafting Implant site assessment TMJ evaluation |
| Prosthodontist | Implant site assessment |

on the assessment of various relatively common patient problems encountered by dentists.

Cases 1 and 2: Impacted teeth in the mixed dentition

One of the more common problems for dentists, orthodontists, and oral & maxillofacial surgeons is to assess the position of impacted permanent teeth for exposure and repositioning into the correct occlusal position. We have all suffered through and continue to use the “Buccal Object Rule” or “SLOB (Same on Lingual, Opposite on Buccal) Rule” to determine the position of impacted teeth.¹¹ The cases below, Figures 1a-1e and 2a-2d, show 2 patients with different permanent tooth impactions and the advantage of having CBCT information for the surgeon and orthodontist.

Case 1: A fifteen year-old white female with an impacted maxillary right cuspid and developing third molars.

Case 2: A fifteen year-old white female with an impacted maxillary right cuspid and developing third molars.

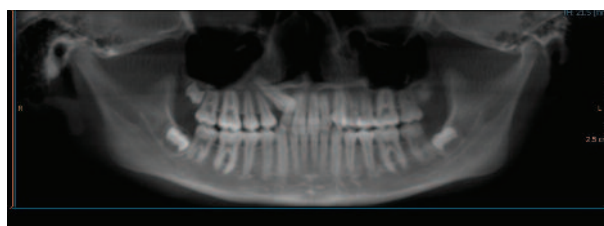

Figure 1a: A reconstructed panoramic image, simulating a conventional panoramic, showing the impaction of tooth #6. From this image, the clinician cannot determine if the tooth is impacted facially or palatally.

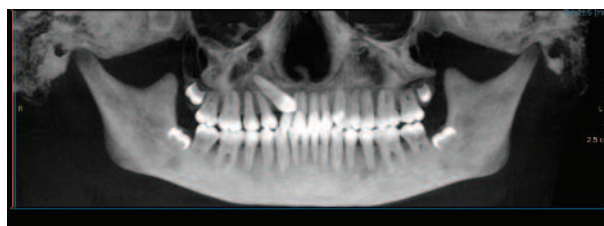


Figure 1b: A reconstructed MIP (Maximum Intensity Profile) image provides improved clarity, but is still inadequate for determining tooth position. Note the complete root formation and the developing third molar follicle positions.

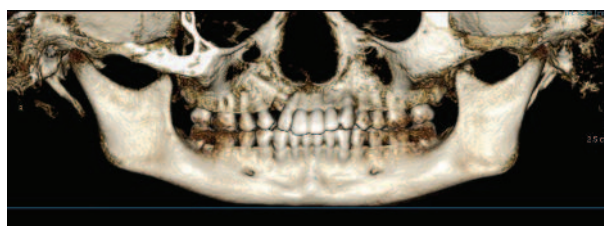

Figure 1c: A 3D reconstructed color image reveals that the cuspid crown is palatal to the lateral incisor. Note the complete lack of space clinically for this tooth.

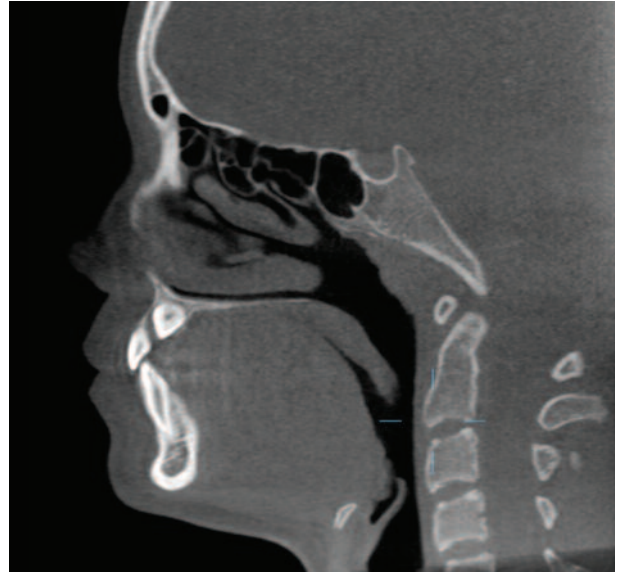
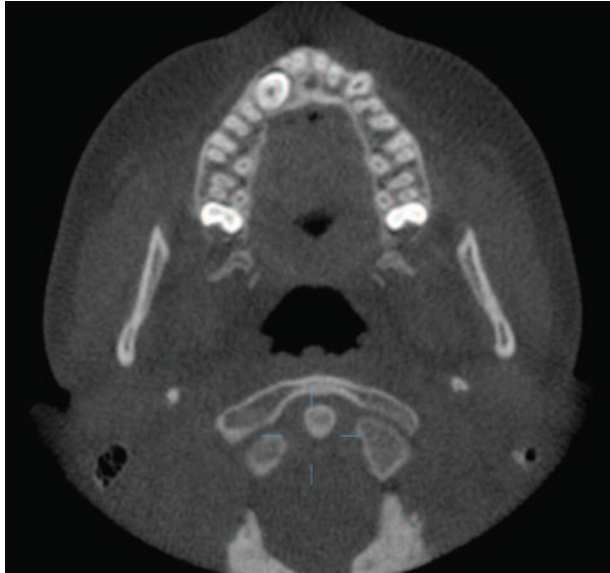
Figure 1d: (left) Axial image showing the crown position of tooth #6. (right) Sagittal view showing the crown position of tooth #6 and its follicular space palatal to tooth #7.

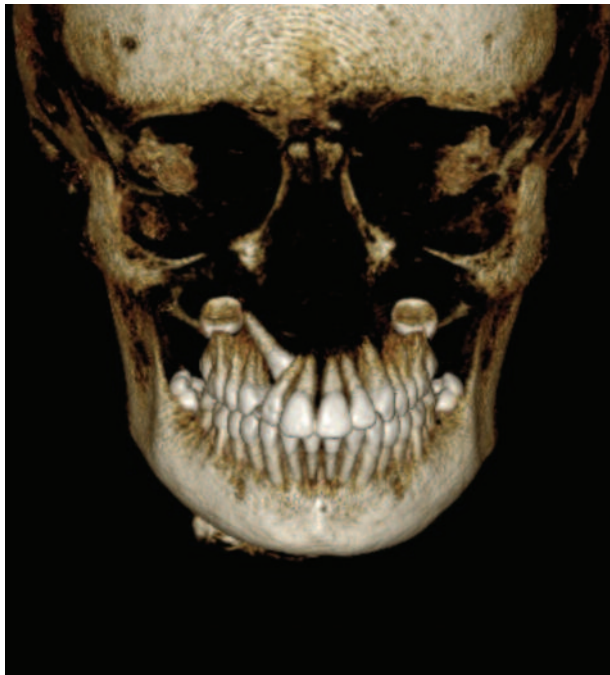


Figure 1e: A 3D reconstructed color image reveals the “true” position of the impacted cuspid. This image and related CBCT images allow for improved surgical planning in comparison to standard digital images.

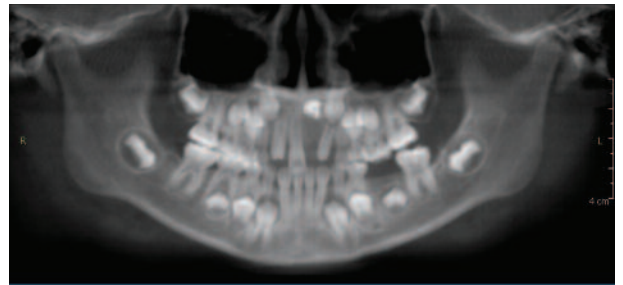


Figure 2a: A reconstructed panoramic image reveals normal tooth development except for tooth #9. In this image the tooth almost appears deformed or even replaced by an odontogenic malformation such as an odontoma.

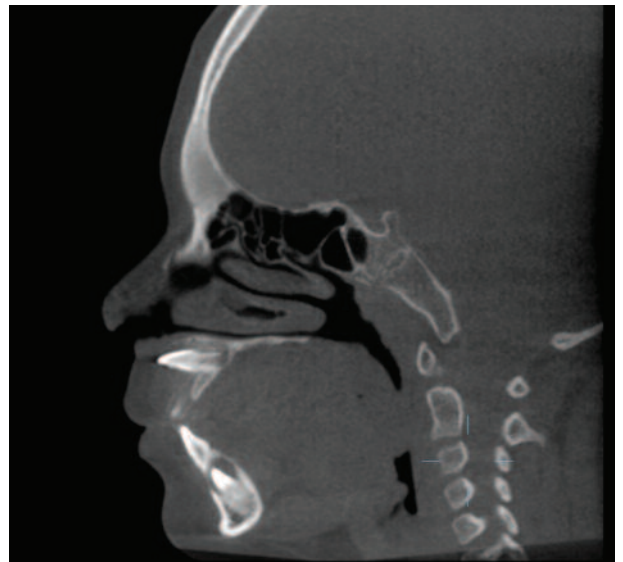

Figure 2b: A sagittal view of this tooth shows normal development of the crown and root, but a very unique horizontal impaction. This image and related CBCT images allow for improved surgical planning in comparison to standard digital images.

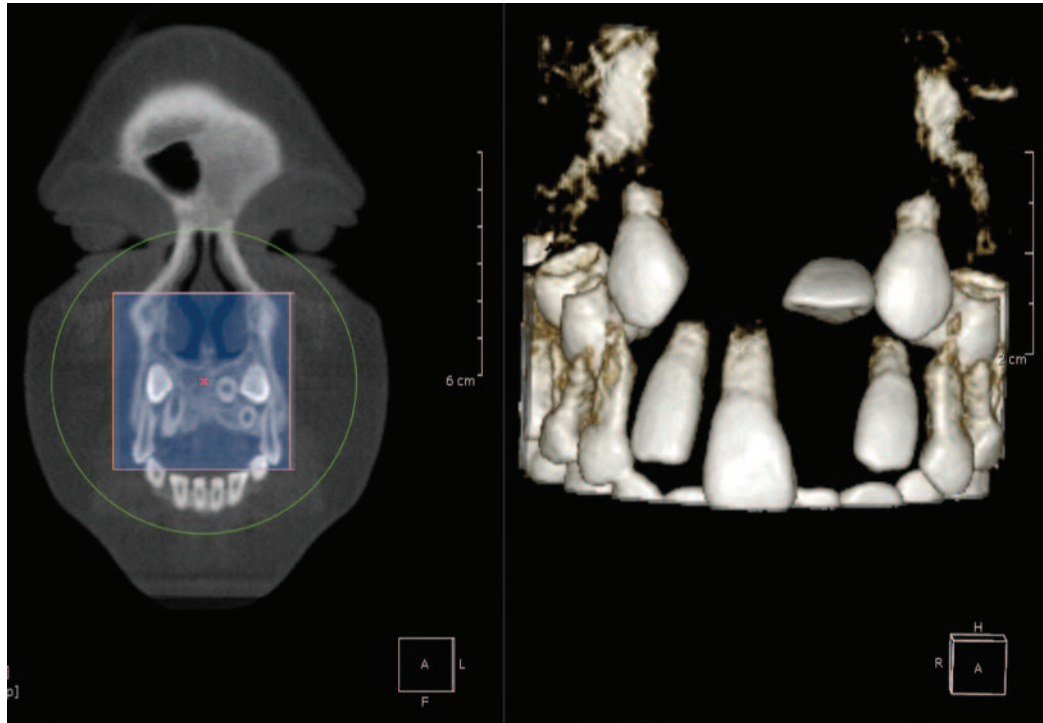


Figure 2c: (left) 3D color reconstruction using a “Cube” tool in OnDemand 3D third party software (CyberMed International, Seoul, Korea) shows the sub-mucosal position of developing teeth #6, 9, and 11. (right) The same image made “transparent” to remove the thin bone and allow better visualization of the dentition.

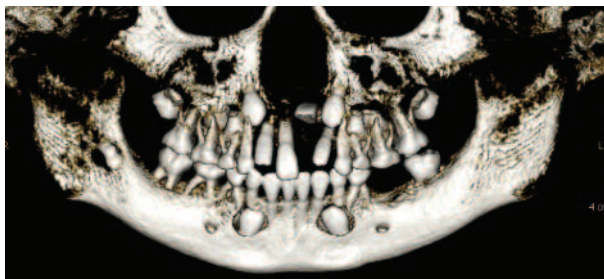


Figure 2d: A 3D color panoramic reconstruction shows all tooth relationships and root development.

Case 3: Pre-surgical implant imaging

Perhaps the most widely adopted application for CBCT to date is implant site assessment. Images from any cone beam machine are rendered in a precise 1:1 ratio in reconstruction software provided by the vendor. Dentistry has never had this capability before. All of our previous image applications (periapical, panoramic, and cephalometric) have been magnified and distorted because of the nature of the image capture. The precise 1:1 ratio of CBCT images allows the

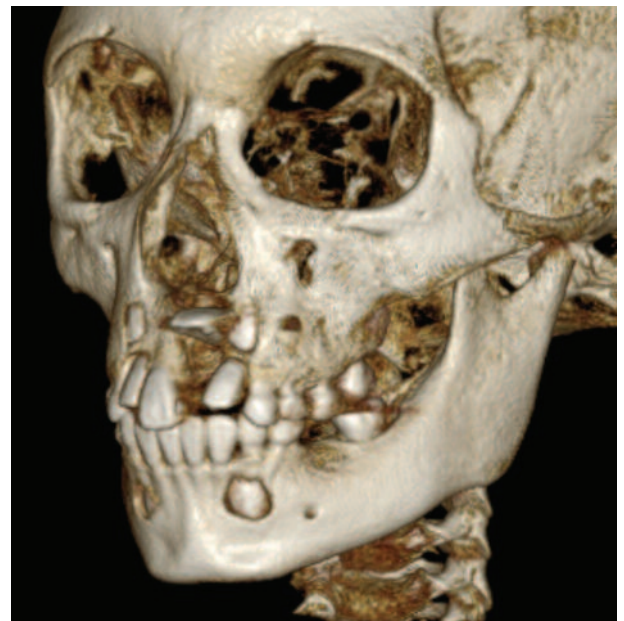

Figure 2e: A 3D color skull reconstruction of the potential problems.

clinician to have very large and accurate implant site images rather than the older “life size” images displayed in medical

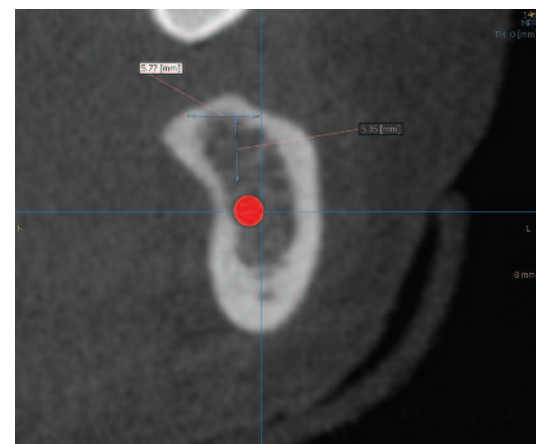
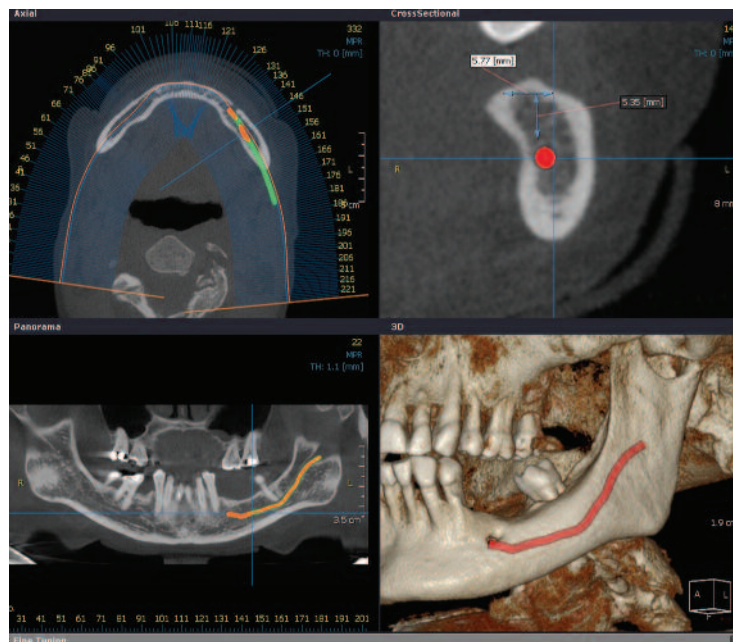
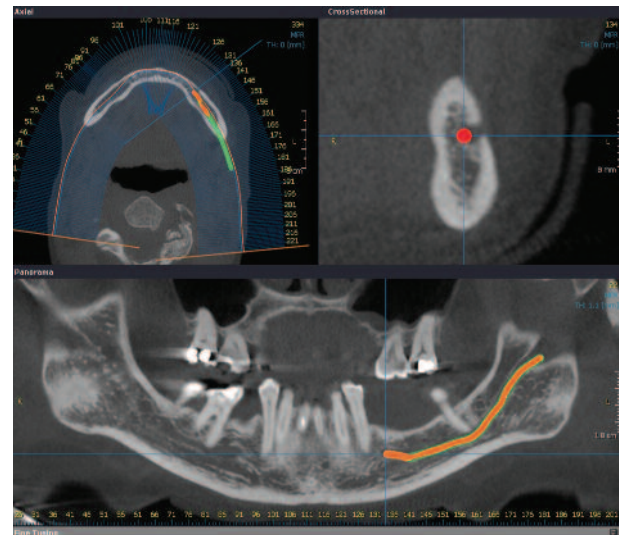


Figure 3a: (left) Multiple views of a proposed implant site. (above) View captured directly in the software, enlarged for planning and displaying to the patient in practice management software. Since image reconstruction is 1:1, the image may be displayed at any size on the monitor or if printed. The measurements depicted are accurate to within 0.1 mm.

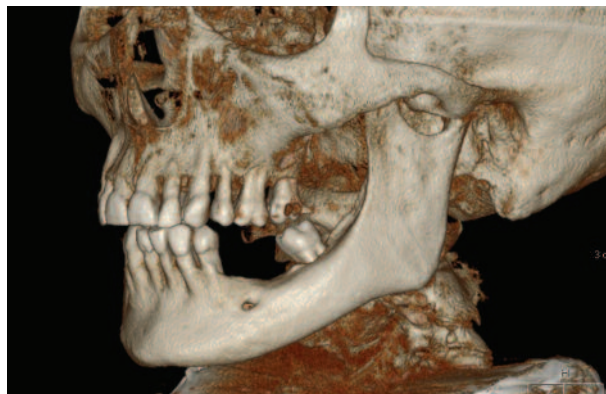

Figure 3b: (above) A 3D color reconstruction of the patient rotated to show left mandible. Note the detail of the bony anatomy. (right) This slice pseudopanoramic used to “paint” the inferior alveolar nerve canal, allows reconstruction of the anterior implant site showing the canal painted in red exiting the mental foramen.



CAT scan software of the past. The width and height of the proposed site are also measured with an accuracy of 0.1mm. Figure 3a illustrates this concept.

Image 3d depicts some of the ways to display implant information available in this third party software (OnDemand 3D, CyberMed International, Seoul, Korea).

Cases 4-5: Assessment of the temporomandibular joint complex

Until now, dentists have had to rely on 2D grayscale images and radiographic interpretations of condylar changes to determine the severity of a condylar problem and how it should be managed. To visualize disc displacement

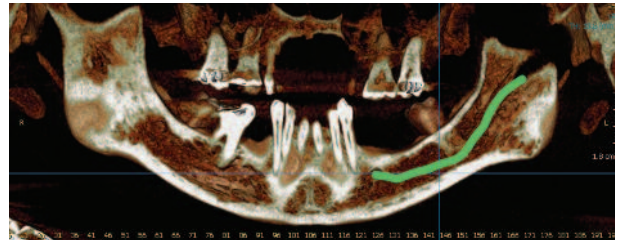
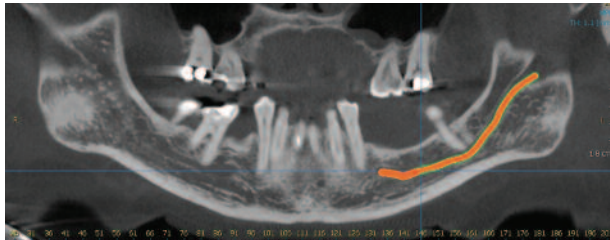


Figure 3c: (top) This slice pseudopanoramic reconstructed at 1.0 mm thickness showing location and path of inferior alveolar nerve canal. **(bottom)** color rendition thickened to about 10mm.

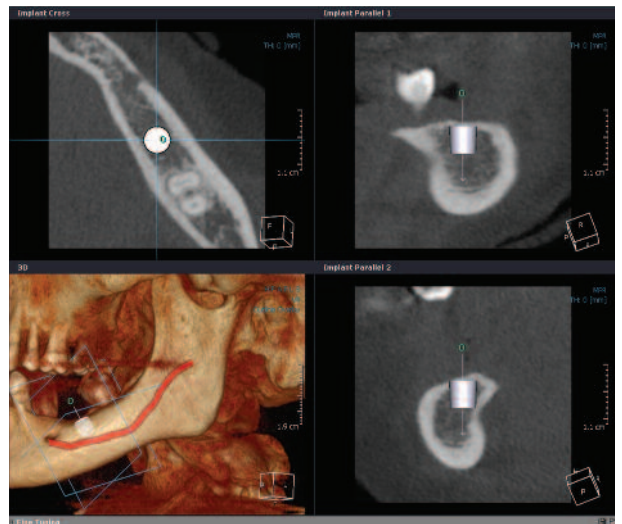
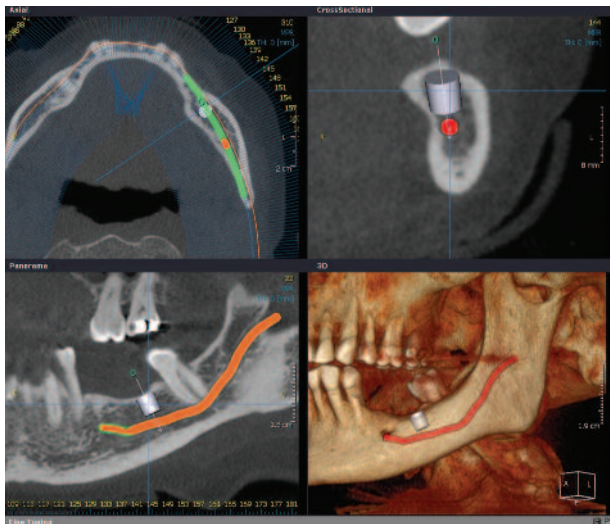


Figure 3d: (left) Selected “mini-implant” placed by operator into site for visualization. **(right)** A “Verification” tool allows precise adjustments to show an implant can be placed, verified in the axial and sagittal views.

problems, we still have to rely on magnetic resonance imaging or arthroscopy to see the “soft tissues” to the TMJ complex. Bony changes, however, are easily and completely imaged by CBCT. Conditions such as osteoarthritic changes, synovial chondromatosis, and rheumatoid arthritis can be seen in color in three dimensions. Additionally, it is simple to correlate vertebral body changes in the cervical spine with condylar and articular eminence changes. The cases below demonstrate this capability.

Case 4

This 59 year-old white female was referred for evaluation of tooth site #14 for implant placement. In addition to chronic sinus changes and a failing implant at another site, the following images depict osteoarthritic changes of the

right TMJ condyle and certain vertebral bodies.

Osteoarthritis (OA) is a common finding in adults and clinicians placing implants and possibly altering the patient's occlusion should always image the TMJ complexes to rule out preexisting problems like OA to ensure success of their case restoratively. In addition, orthodontists are justifying scanning patients in “adult orthodontic cases” to assess any joint problems which could alter the progress of their case.

Case 5

This 68 year-old white female was referred for a preliminary assessment for orthodontic treatment. This case demonstrates a bilateral occurrence of “loose bodies” or synovial chondromatosis.

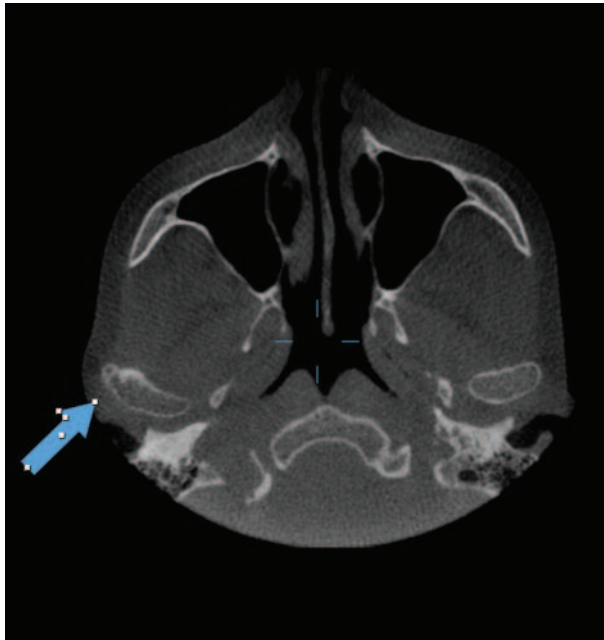


Figure 4a: Axial "slice" through the mid-condyle region showing a "cystic lesion" on the lateral pole of the right condylar head (blue arrow).

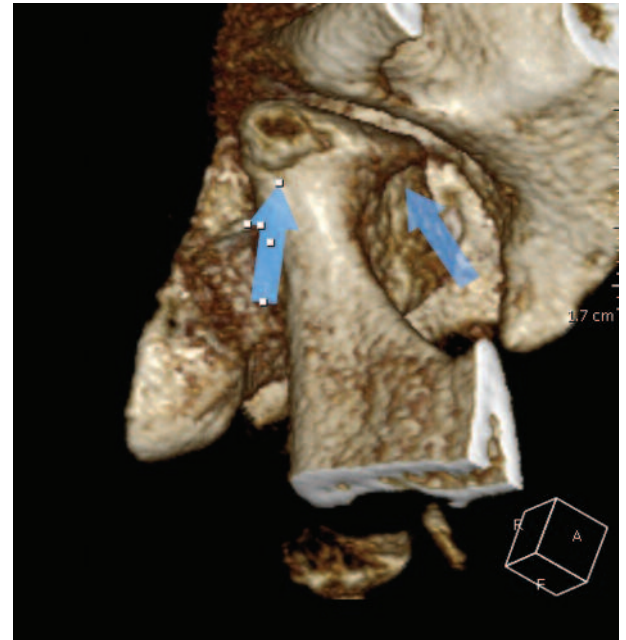

Figure 4b: 3D color reconstruction of the right TMJ condyle and related bony elements showing the osteophyte formation and subchondral cyst on the lateral pole as well as some osteophyte formation on the anterior surface (blue arrows).

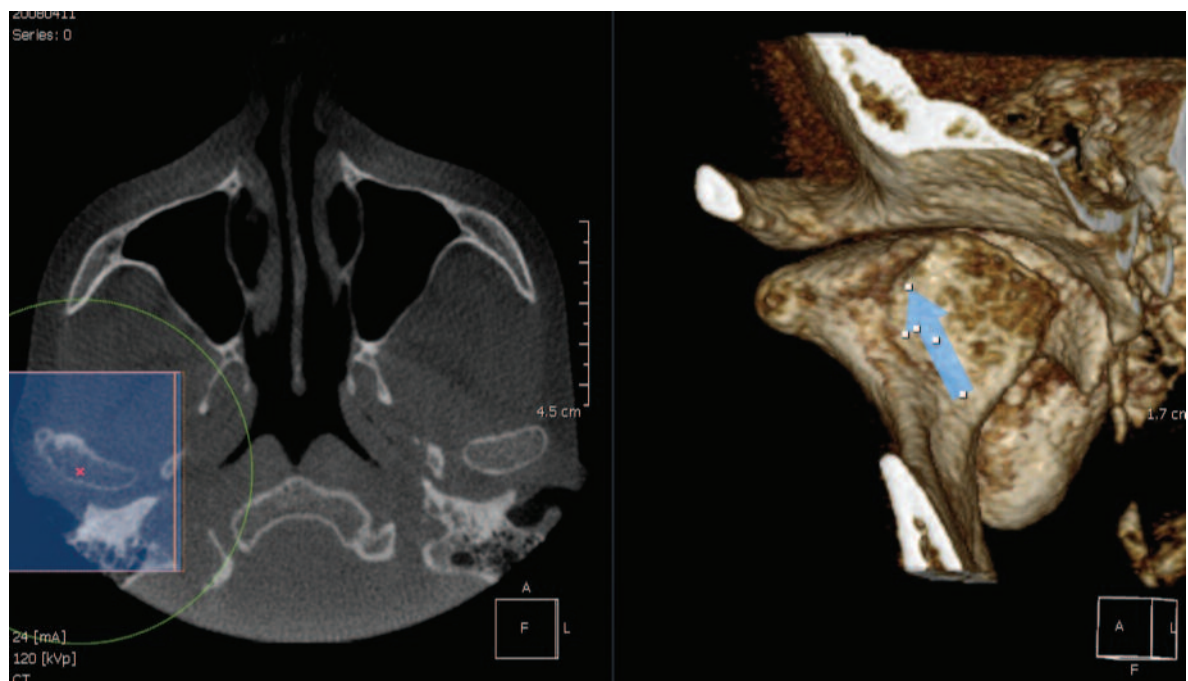


Figure 4c1: 3D color reconstruction of right TMJ complex.

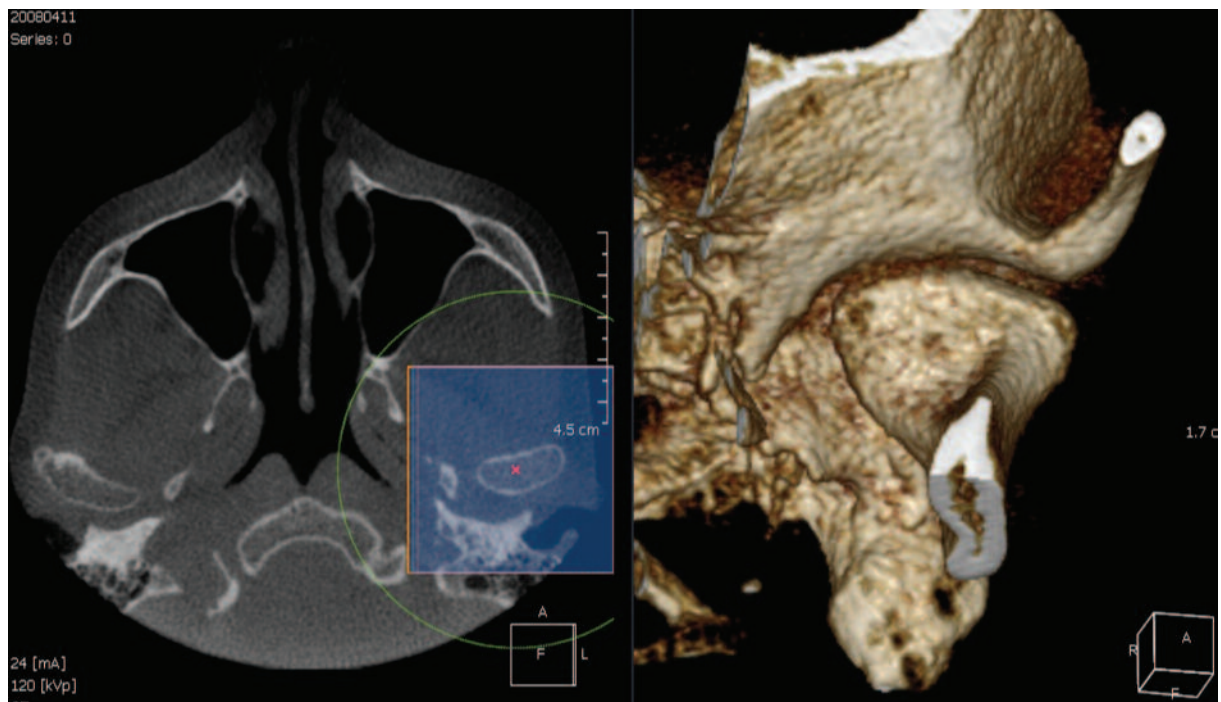


Figure 4c2: The same process applied to the left TMJ complex for comparison showing a normal condylar head.

Conclusion

In Part I of this article I've briefly discussed some current machines and common applications of CBCT. This part, called "the Ecstasy", used many cases to illustrate the power of these images for clinical decision making. The reader simply needs to look at the axial views and 3D color reconstructions to know that this technology will help them in their dental practice. Each picture is, for the most part, worth 1000 words. In part II of this series, I will present the downside of this technology: "The Agony." That is, the need for additional education if you're going to adopt cone beam imaging and the absolute need for a formal radiographic report from an oral & maxillofacial radiologist or medical radiologist with most cases.

Disclosure

The author reports no conflicts of interest with any products mentioned in this article.

Reprinted with permission by The Journal of Implant and Advanced Clinical Dentistry. ©2009

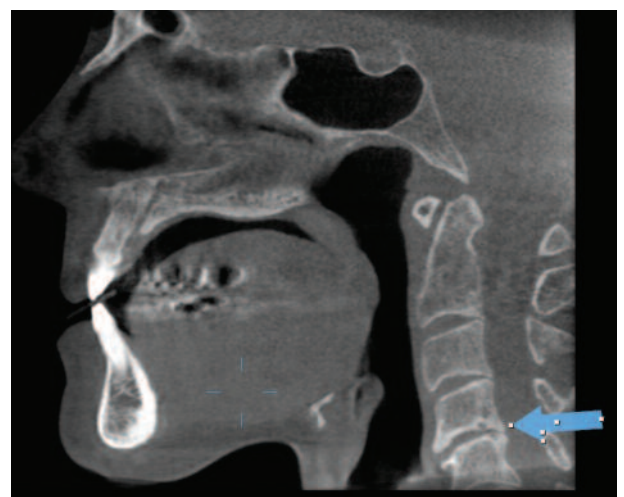


Figure 4d: Midline sagittal view of the vertebral column showing osteophyte formation, subchondral sclerosis and subchondral cyst formation on C4 and C5. These images confirm osteoarthritis of the C-spine and TMJ condyles.

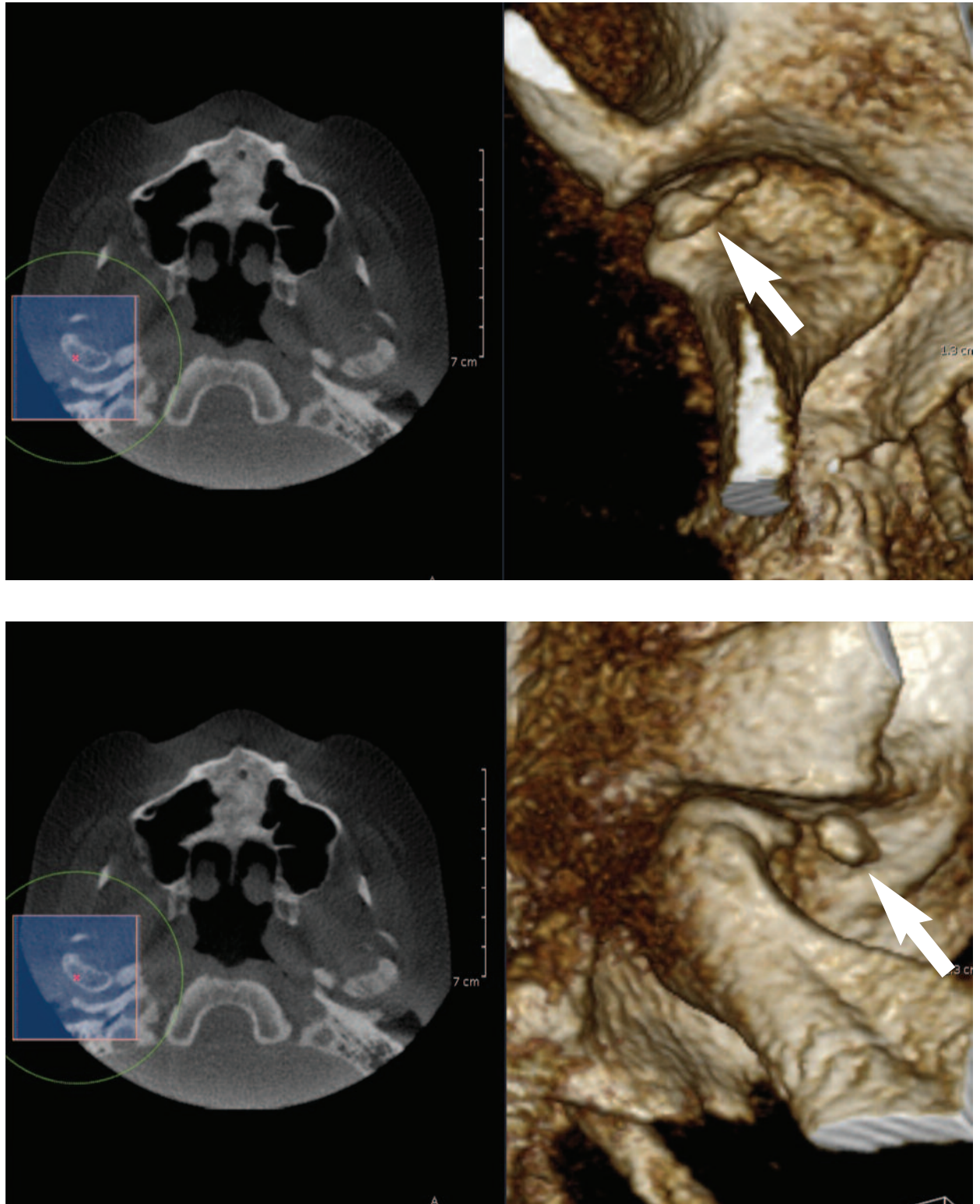


Figure 5a: A-P (top) and sagittal (bottom) image 3D color reconstructions of the right TMJ complex showing the "loose body" anterior to the lateral pole of the condyle.

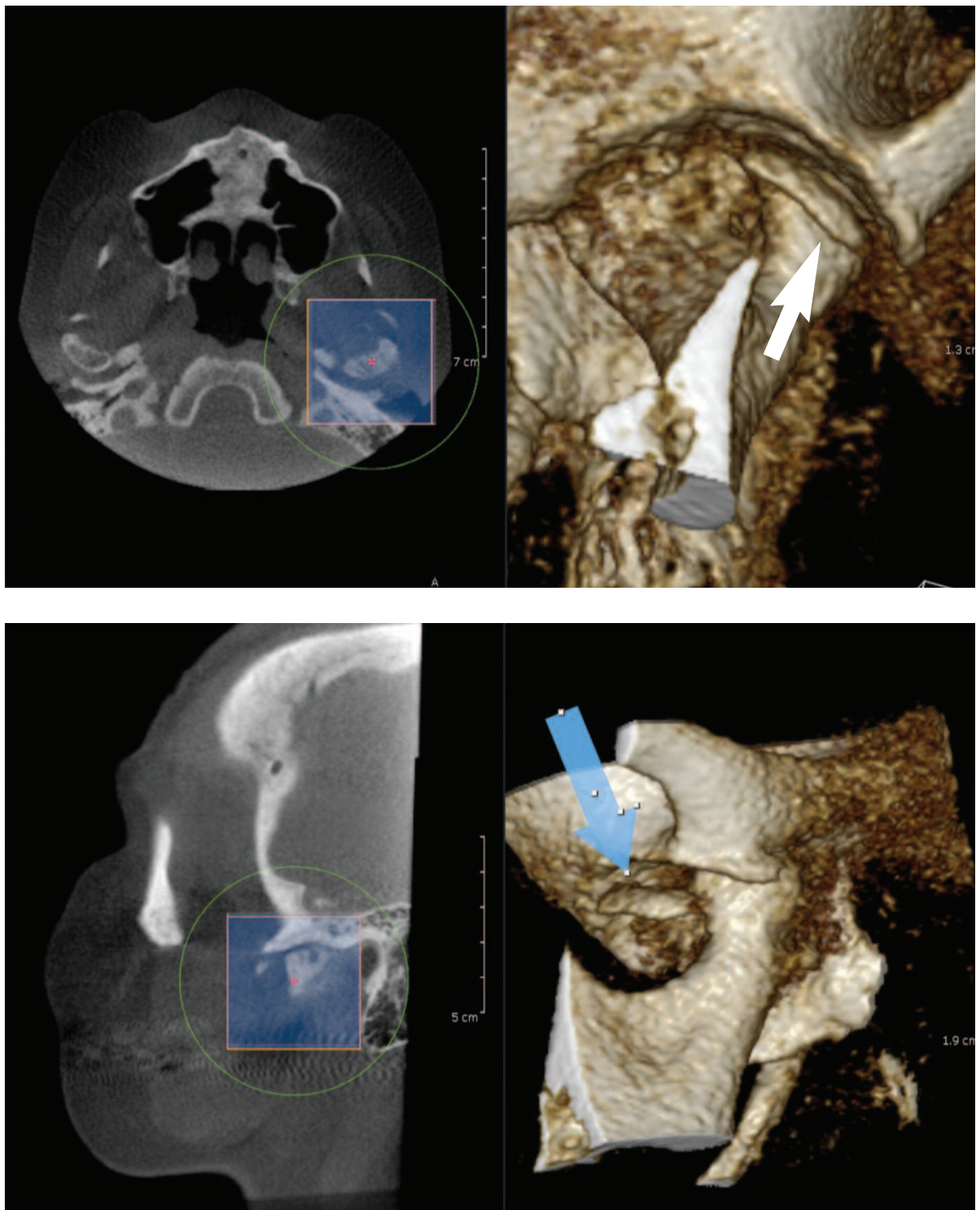


Figure 5b: A-P (top) and sagittal (bottom) 3D color reconstructions of the left TMJ complex showing the “loose body” anterior to the lateral pole of the condyle (white arrow, top image and blue arrow, bottom image).

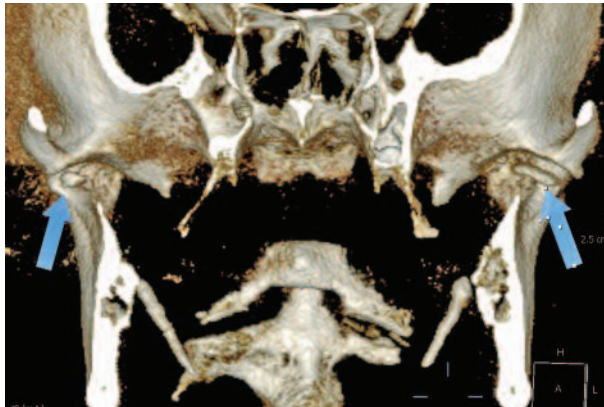


Figure 5c: A-P 3D color reconstructions of the right and left TMJ complexes showing the “loose body” anterior to the lateral pole of the condyle (blue arrows). Note also the calcified elongated stylohyoid ligaments.

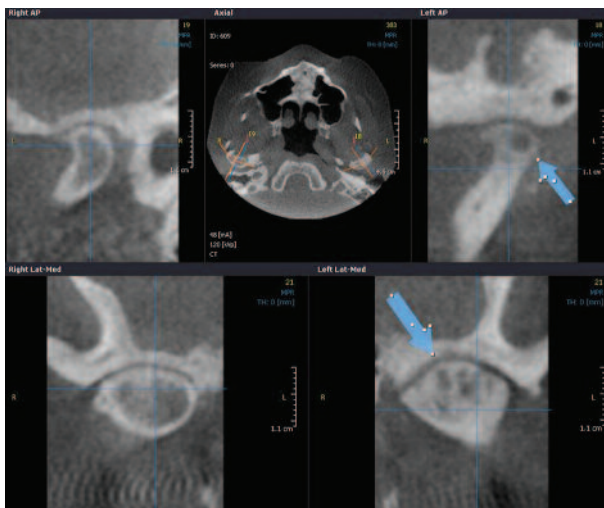


Figure 5d: Side-by-side comparison of the right and left condyles in the “TMJ” program showing subchondral cyst formation in the condylar heads.

References

1. Danforth R, Mah J. 3-D Volume for Dentistry: A New Dimension. CDA Journal 2003; 31(11): 817-823.
2. Cattaneo PM, Melsen B. The use of cone-beam computed tomography in an orthodontic department in between research and daily clinic. World J Orthod 2008; 9(3): 269-82.
3. Miles D, Danforth R. A Clinician’s Guide to Understanding Cone Beam Volumetric Imaging. Academy of Dental Therapeutics and Stomatology Special Issue 2007; 1-13.
4. Nakajima A, Sameshima G, Arai Y, et al. Two and three-dimensional orthodontic imaging using limited cone-beam computed tomography; Angle Orthod 2005; 75: 895–903.
5. Scarfe W, Farman A, Sukovic P. Clinical applications of cone-beam computed tomography in dental practice. J Canadian Dent Assoc 2006; 72: 75–80.
6. Bourgeois M, Sikorski P, Taylor S. Cone Beam Volumetric Tomography. Oral Health 2007; 6: 14-16.
7. Miles D. Clinical Experience with Cone-Beam Volumetric Imaging – Report of Findings in 381 cases. US Dentistry 2006; 1(1): 39-42.
8. Danforth R, Miles D. Irish Dentist 2007; 10(9): 14-18.
9. Miles D: Color Atlas of Cone Beam Volumetric Imaging for Dental Applications. Quintessence. 2008: 47-303.
10. Miles D. The Future of Dental and Maxillofacial Imaging. Dent Clin N Am 2008; 52(4): 917–928.
11. Miles D, VanDis M, Williamson G, Jensen C. Radiographic Imaging for the Dental Team. SAUNDERS Elsevier, 4th Ed. 2008: 17-18.

Dr Dale Miles is a keynote speaker at Vision Congress Jhb – 8 June 2012